

## An Unusual Type of Olecranon Fracture in A Forty Year Old Lady.

Dr. Pradip Kumar Ghosh<sup>1</sup>, Dr. Soudip Sinha<sup>2</sup>,  
Dr. Debkumar Ray<sup>3</sup>, Dr. Chiranjit De<sup>4</sup>, Dr. Anindita De<sup>5</sup>, Dr. Arnab Samanta<sup>6</sup>

<sup>1,2,4,6</sup>Department Of Orthopaedics & Traumatology, Burdwan Medical College & Hospital,

<sup>3</sup>Department Of Biochemistry, Burdwan Medical College, Burdwan

<sup>5</sup>Department of Community Medicine, Burdwan Medical College, Burdwan

**Abstract:** Olecranon fractures are usually managed as per Schatzker's Classification. Our case presented with an unusual pattern which was not fitting with Schatzker's Classification (Fig-1). It was managed as per standard AO principle of fracture management. It showed satisfactory result.

**Keyword:** Olecranon fracture; unusual pattern.

### • Introduction

Fracture of olecranon is one of the common fractures of upper extremity. These fractures has been classified by Schatzker based on fracture pattern and mechanical consideration as to the type of internal fixation required<sup>1</sup>. We are going to report an olecranon fracture with unusual fracture geometry which is not fitting with Schatzker classification. It has been reduced and fixed under vision with a pre-contoured low profile locking plate and with a lag screw. Short follow up of one year shows satisfactory result.

### • Materials And Method

A forty year old lady presented at emergency department of Burdwan Medical College & Hospital with pain and swelling of her left elbow following fall from a standing height two hours back. There was moderate tenderness over the olecranon. There was no neuro-vascular deficit. The elbow was clinically stable. Overlying skin was normal. There was no other injury found in the body. The patient was immediately advised for regional skiagram of the left elbow. It showed a fracture involving the whole olecranon process (Fig-2). The fracture geometry was unusual. It was having a 'L'-pattern. The sagittal plane was the longitudinal arm of the 'L' and the coronal plane was the horizontal arm. The sagittal split partially involved the articular surface of the olecranon.

Long arm Plaster of Paris (POP) backslab was immediately applied and analgesics were prescribed. This patient was posted for operation on next day after pre-anaesthetic check up.

Under brachial block the patient was placed in right lateral position. A 6 cm skin incision was made from the tip of the olecranon process to an adequate distance distally for good exposure. On exposure the separated fracture fragment was found to be present medially (Fig-3). It was having adequate soft tissue attachment. The fracture surface was carefully cleaned and reduced under vision. Fracture was provisionally fixed with Kirshner's wires and an interfragmentary 3.5mm lag screw (Fig-4). After provisional reduction a precountoured low-profile olecranon lock plate was applied and fixation was completed with four 3.5mm locking screws (Fig-5). Elbow was found stable clinically. Reduction and fixation were checked under image intensifier. Wound was closed in layers. A POP back slab was applied with the elbow in 90° flexion.

### • Result

Dressing was changed on the 3<sup>rd</sup> day and the POP back slab was removed. The patient was encouraged for active elbow movement on 3<sup>rd</sup> post-operative day onwards. Stitches were removed after 2 weeks. The wound was healthy. Patient was followed up regularly. The patient is having no complain at present. Patient showed near normal range of elbow movement 6<sup>th</sup> month onwards the surgery (Fig-6,7).

### • Discussion

Fracture of olecranon is one of the common fractures of upper extremity starting from children and upto old age. These fractures can be caused by either direct trauma, such as falling on the tip of the elbow or indirectly by a counter acting force of the triceps muscle in a partially flexed elbow. These fractures has been classified by Schatzker based on fracture pattern and mechanical consideration as to the type of internal fixation required.

The goal of treatment of olecranon fracture is restoration of elbow function without pain. Anatomical reduction and stable internal fixation are vital for both function and prevention of arthrosis. Implementation of an

early range of motion program will decrease the chances of post traumatic arthrofibrosis making stable internal fixation mandatory.

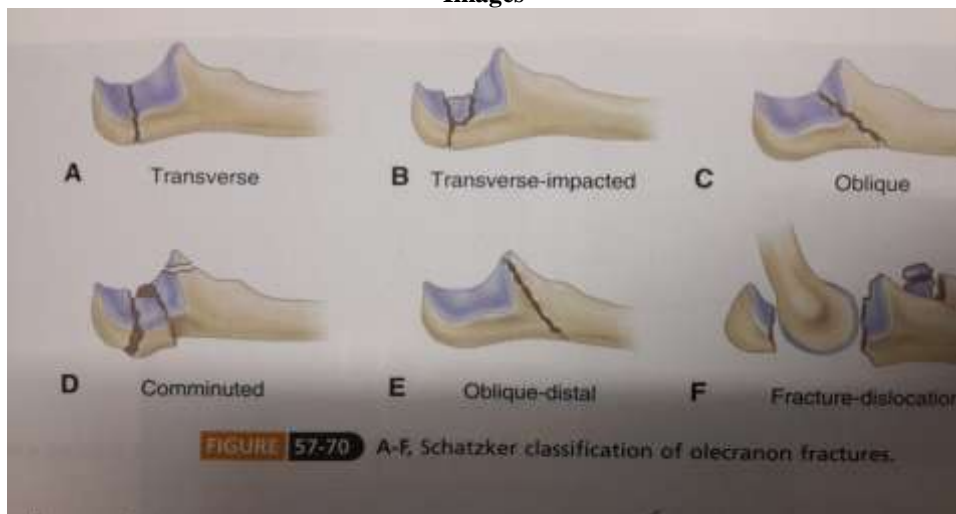
In this case the fracture pattern was unusual. It was not fitting with most commonly used Schatzker classification. As radiological evidence was very much obvious so CT Scan was not done in this case. The mechanism of this type of injury is probably a direct trauma.

We have followed the standard AO principle for fracture fixation. The end result of short follow up shows excellent result.

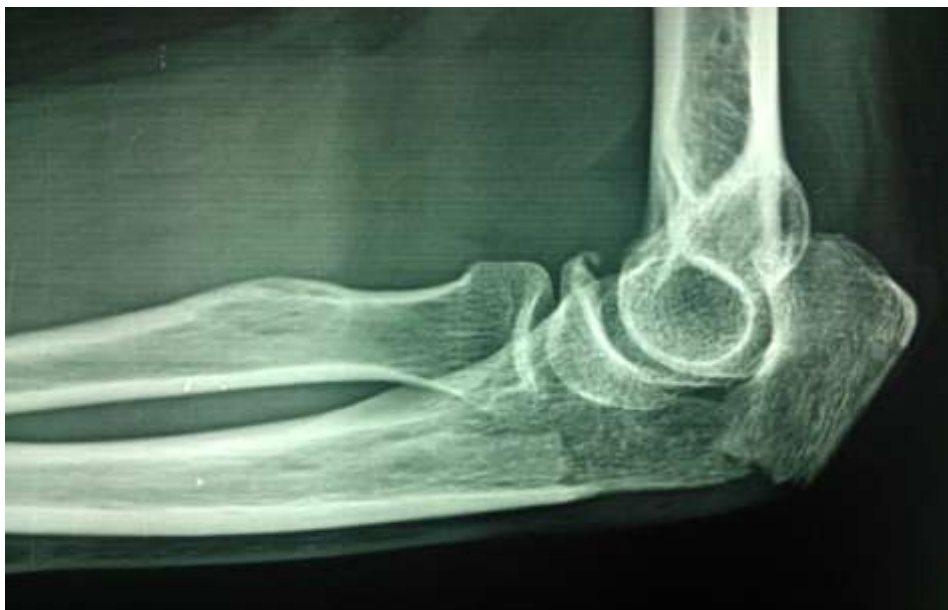- **Conclusion**

Unusual fracture pattern in this case has not been found in the literature. Following AO principle of fracture fixation this case showed satisfactory result.

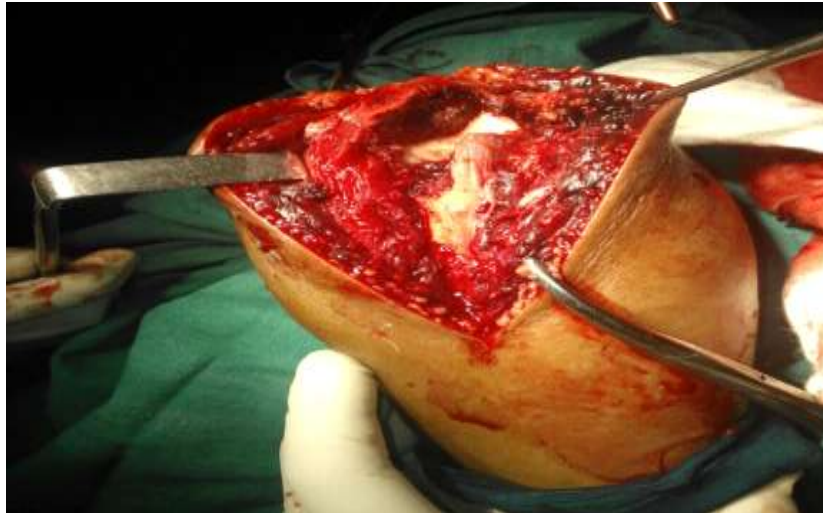
**Images**



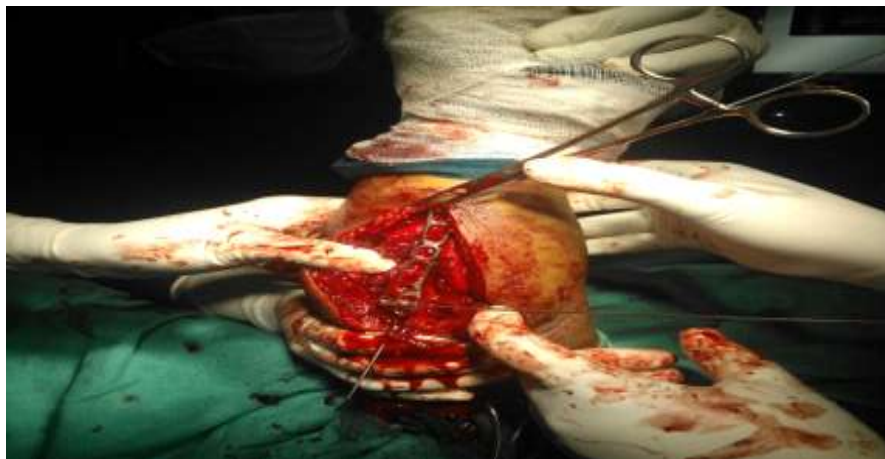**Fig-1:** Schatzker's classification of olecranon fracture.



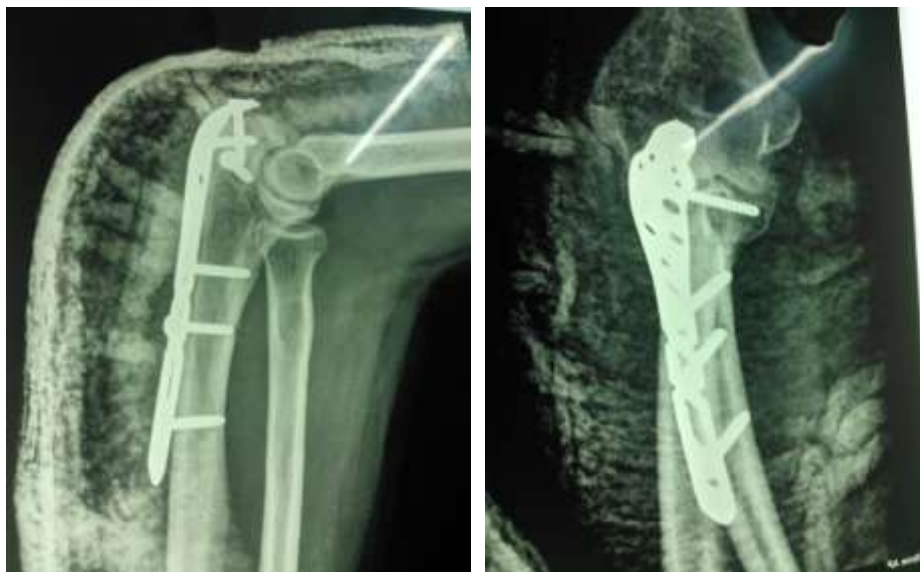**Fig-2:** Pre-operative skiagram showing fracture of olecranon.



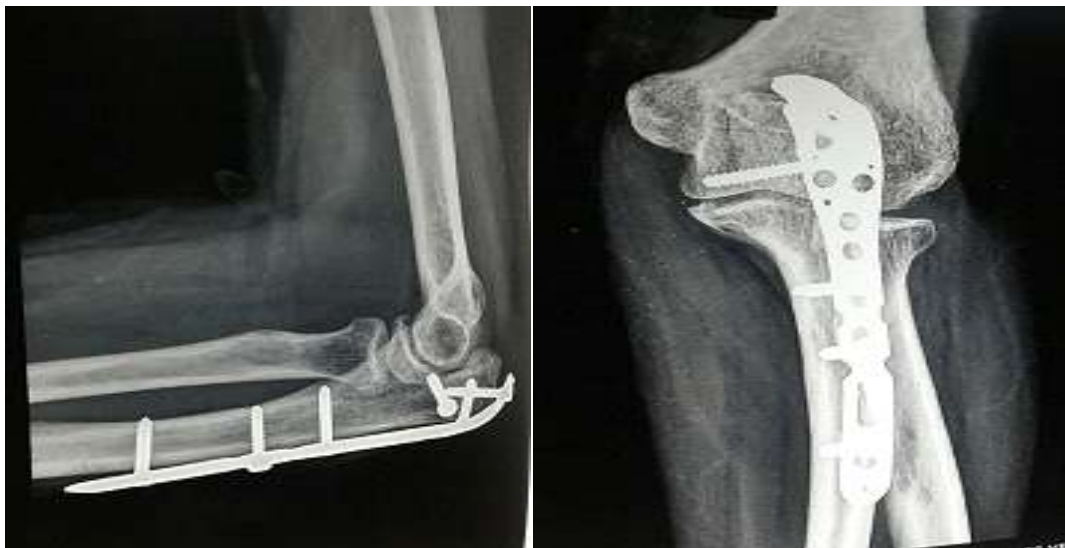**Fig-3:** Intra-operative photograph showing fracture geometry.



**Fig-4:** Provisional fixation with K-wire & precontour lock plate.



**Fig-5:** Immediate post-operative skiagram.



**Fig-6:** Post-op skiagram at 1 year.



**Fig-7:** Post-operative clinical photo showing normal range of elbow motion.

#### References

- 1.S. Terry Canale, James. H. Beaty. Campbell's Operative Orthopaedics;(12<sup>th</sup> edition), vol-3,page no: 2879-2880.
- 2.Rockwood and Green's Fracture in Adults;(8<sup>th</sup> Edition),Vol-I, Page: 1219-1221.
- 3.Thomas P Ruedi ,Richard E Buckley,Christopher G Morgan. AO Principles of Fracture Management(2<sup>nd</sup> Edition);Vol-2, page no: 631-634.